

# Transpulmonary pressure measurement

## Benefit of measuring transpulmonary pressure in mechanically ventilated patients

Dr. Jean-Michel Arnal, Senior Intensivist, Hopital Sainte Musse, Toulon, France

Dr. Dominik Novotni, Manager of Research and New Technology, Hamilton Medical, Bonaduz, Switzerland

### Introduction

In mechanical ventilation, basic monitoring combines airway pressure and flow. While the titration of ventilator settings based on measurement of airway pressure may be adequate for most mechanically ventilated patients, we know that this is an oversimplified surrogate for the pressure in the two components of the respiratory system, namely the lungs and the chest wall. It is now widely accepted that chest wall mechanics can be severely abnormal in critically ill patients<sup>1, 2, 3</sup>. As part of a continuous effort to improve lung protection, the contribution of chest wall mechanics should not be ignored. Consequently, advanced monitoring in mechanical ventilation includes the measurement of esophageal pressure, which is considered to be a substitute for pleural pressure. Partitioning of lung and chest wall compliance is then possible and is very useful to assess lung recruitability, perform recruitment maneuvers, and to set PEEP and tidal volume. Transpulmonary pressure is airway pressure minus esophageal pressure measured during an end-inspiratory or end-expiratory occlusion, and represents the pressure to distend the lung parenchyma. Transpulmonary pressure may allow customization of ventilator settings in order to optimize lung recruitment and protective ventilation in mechanically ventilated patients.<sup>4</sup>

### Contraindications

The contraindications are rare and are basically the same as for a nasogastric tube. Use of an esophageal catheter is contraindicated in patients with diseases such as esophageal

ulcerations, tumors, diverticulitis, bleeding varices, recent esophageal or gastric surgery, sinusitis, epistaxis, or recent nasopharyngeal surgery.

### Placement technique

#### Preparation

The adult esophageal balloon catheter kit contains an 86 cm closed-end catheter with a 9.5 cm balloon and a stylet together with a pressure extension tube and a 3-way stopcock. An additional extension line and a 3 to 5 ml syringe are needed. A topical anesthetic (e.g., lidocaine spray) is required in awake patients (Figure 1).

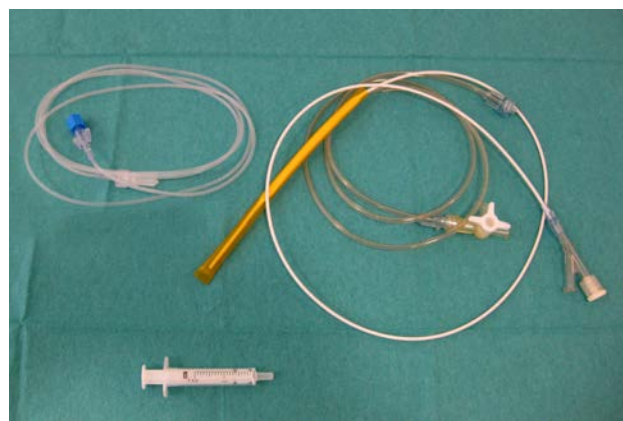


Figure 1: The adult Cooper Surgical Esophageal Balloon Catheter kit

Unpack the catheter and attach the 3-way stopcock directly to the esophageal catheter. Inflate the balloon with a large volume (NutriVent: 6 ml, Cooper: 3 ml), then check the integrity and tightness of the balloon with your fingertips, applying gentle pressure to the balloon.

Connect the extension line to the auxiliary port of the ventilator. Select the display with - from the top down - airway pressure, esophageal pressure, transpulmonary pressure, and flow. Check that esophageal pressure is zero on the waveform (Figure 2).

Placement and measurement of esophageal pressure is easier and more accurate in patients in a semi-recumbent position.

### Placement

The catheter has depth markings to aid in positioning the balloon in the lower third of the esophagus. The estimated depth at which to place the catheter can be measured by the distance from nostril to ear tragus to xyphoid, or calculated as the patient's height (in cm) x 0.288 (Figure 3).

### Step 1

The catheter is inserted through the nostril or the mouth. Select a nostril without obstruction and apply a suitable topical anesthetic if the patient is awake. Apply water soluble lubricant to the distal tip of the catheter.

### Step 2

With the patient's head in a neutral position or flexed slightly forward, slowly insert the catheter through the nostril and hypopharynx using a gentle advancing motion. If the catheter meets obstruction, do not force it. Remove the catheter and insert it through the other nostril. Gently insert the catheter as far as the stomach, which is around 15 cm deeper than the estimated depth (Figure 4).

### Step 3

Attach the extension tube to the Y-connector of the stylet. Actively deflate the balloon with the syringe to ensure the balloon is completely deflated. Inflate the balloon with 3 ml of air using the 3-way stopcock, then withdraw 2 ml to leave 1 ml of air in the balloon. Turn the stopcock to the syringe off and open it to the extension line. Change the timescale of the real-time waveforms to 60 seconds resolution (66 seconds on the HAMILTON-C6).

Check the esophageal pressure measurement on the ventilator. Esophageal pressure should increase during inspiration and should increase during a gentle manual compression of the abdominal left upper quadrant. If the esophageal pressure waveform is similar to airway pressure with the same pressures measured during an end-inspiratory occlusion, tracheal placement may be assumed. Deflate the balloon and remove the catheter. Insert the catheter through the other nostril.

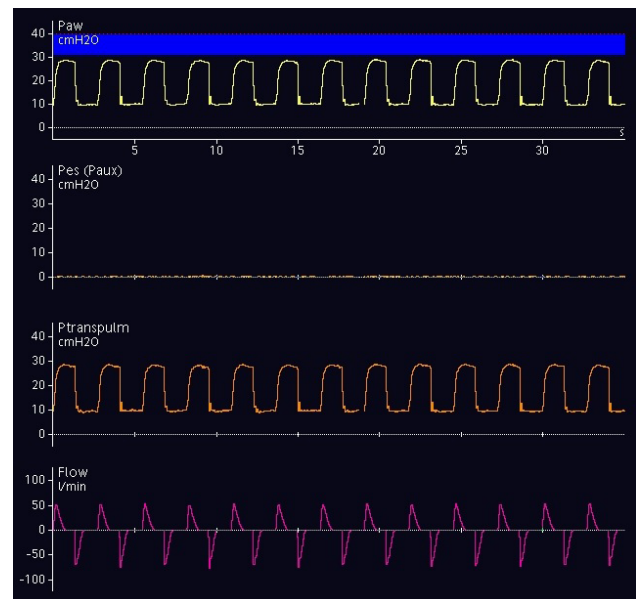


Figure 2: Display of pressures and flow on the ventilator

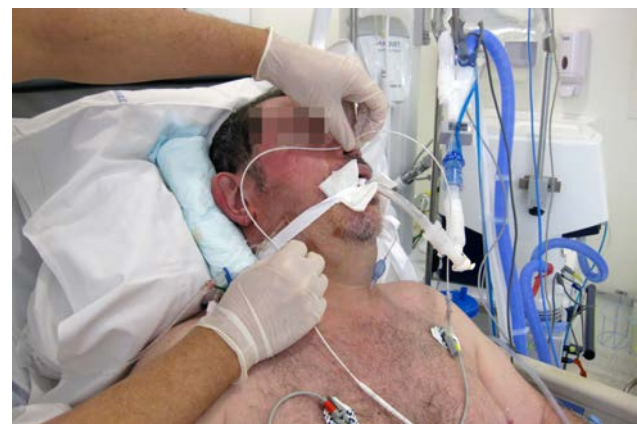

Figure 3: Estimation of the depth to place the catheter

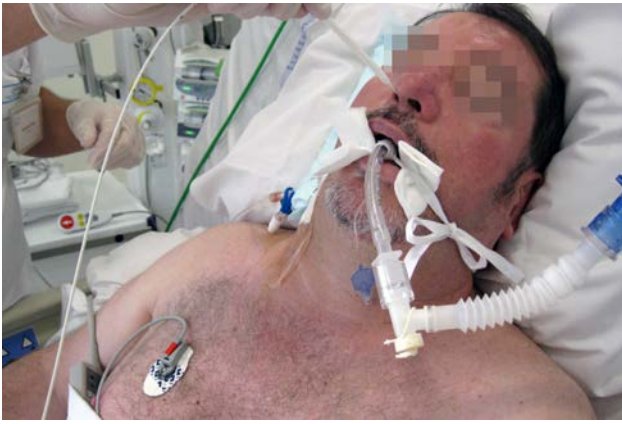

Figure 4: Insertion of the catheter

#### Step 4

Slowly pull out the catheter to the estimated depth. A qualitative change in the esophageal pressure waveform should be seen with the appearance of cardiac oscillations. In spontaneously breathing patients, esophageal pressure should be negative during inspiration. In passive patients, esophageal pressure is positive during insufflation (Figure 5). The middle third of the esophagus is where the pressure measurement is more stable, consistent and less affected by external structures. However, the catheter should be positioned where Ppl (pleural pressure) is best defined as confirmed by the occlusion test (verification of the correct position).

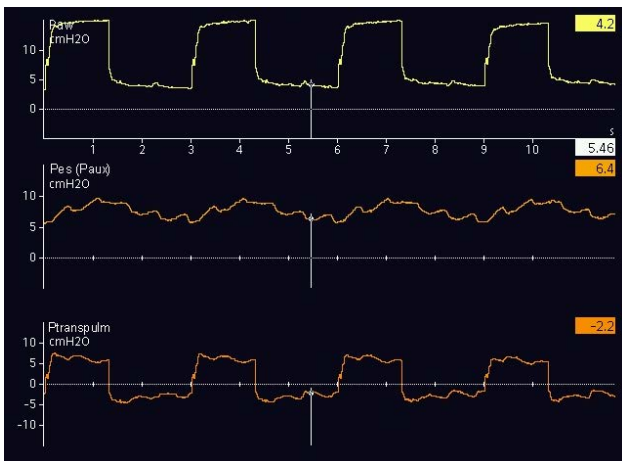


Figure 5: Placement of an esophageal catheter in a passive patient. Esophageal pressure increases during insufflation. The small waveforms are cardiac oscillations

#### Step 5

When the balloon is in the proper position and the measurement is validated, disconnect the extension tube and remove the stylet. Connect the extension tube directly to the catheter and inflate the balloon again (see step 3). Secure the

catheter with tape to prevent motion removal or displacement (Figures 6 and 7). Never attempt to reinsert the stylet once removed.

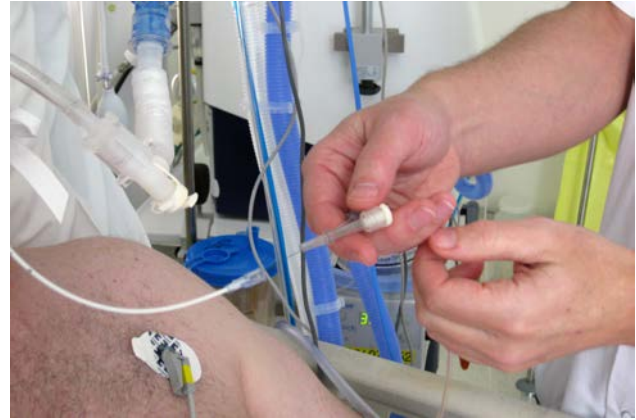

Figure 6: Removal of the stylet and connection to the extension tube

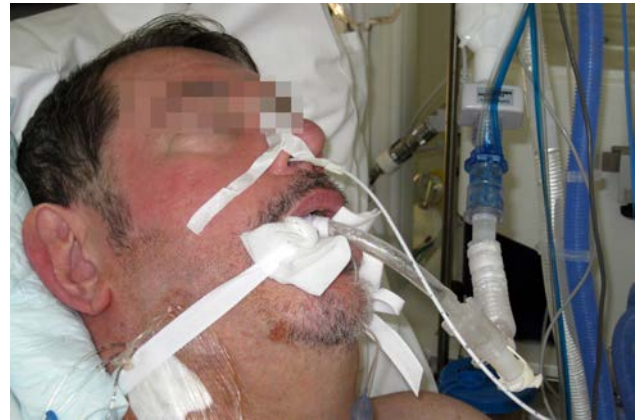

Figure 7: Secure the catheter with tape

If esophageal pressure is measured continuously, repeat step 3 every 30 minutes.

Upon completion of the pressure measurements, deflate the balloon prior to catheter removal.

## Troubleshooting

### Esophageal pressure is similar to airway pressure

Measure airway and esophageal pressures at end-inspiration and end-expiration using an end-inspiratory and end-expiratory occlusion, respectively. If they are similar, the esophageal catheter has probably been inserted in the trachea. Deflate the balloon and remove the catheter.

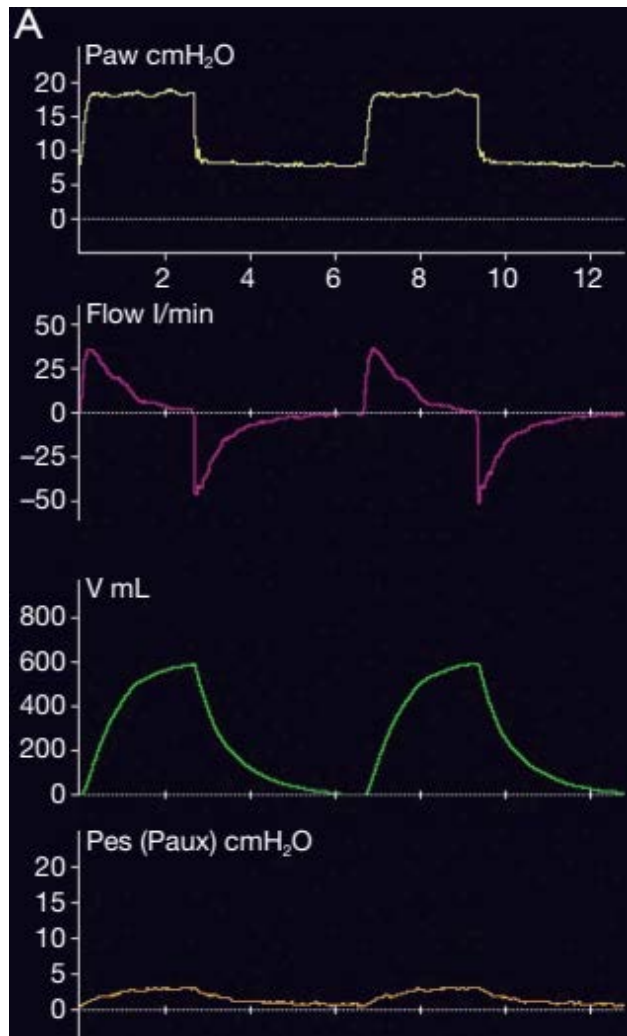


Figure 8: There may not be enough air in the balloon

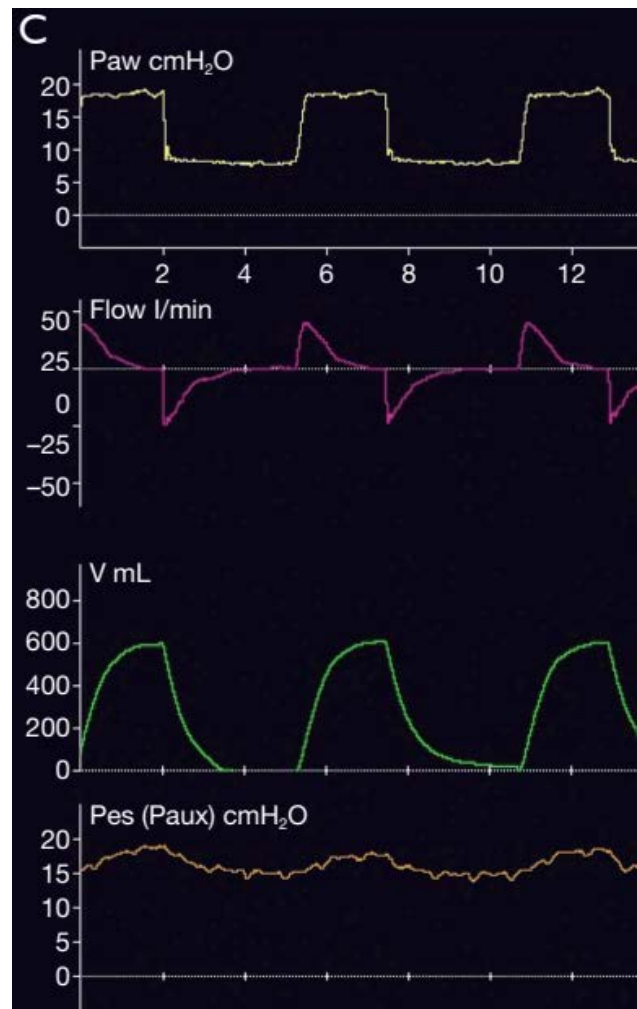


Figure 9: There may be too much air in the balloon

### There is no pressure waveform

Check that the connections are adequate. The catheter may need to be inserted further into the esophagus or may be kinked and needs to be withdrawn.

### Excessive cardiac oscillations prevent reliable measurements

Changing the angle of the bed to have the patient in more of a seated position or withdrawing the catheter a few centimeters can, in some cases, decrease cardiac artifacts.

### Verification of the correct position

Spontaneously breathing patient: The validity of esophageal pressure measurement can be assessed using the dynamic occlusion test procedure. Patients make three to five inspiratory efforts while airways are occluded at the end of expiration. The correct position of the esophageal balloon is ascertained from the high correlation between swings in airway and esophageal pressure during this maximal effort. The

acceptable range of  $\Delta P_{es}/\Delta P_{aw}$  during the dynamic occlusion test is from 0.8 to 1.2<sup>4, 5</sup>. If the patient is not breathing spontaneously (passive condition), the occlusion test is performed by applying manual compression on the chest during an airway occlusion.

More recently, Yoshida et al. proved that  $P_{es}$  measured in the supine position is a good mid-chest surrogate of  $P_{pl}$  in an animal model and human cadavers. In this study, absolute  $P_{es}$  values fall between those of the dorsal and ventral  $P_{pl}$  values measured with direct pleural sensors, thus reducing the clinical significance of the so-called postural artifact<sup>6</sup>.

## How to interpret esophageal pressure

Airway pressure is the pressure of the whole respiratory system (lung and chest wall). Esophageal pressure is an assessment of pleural pressure, i.e., the pressure to distend the chest wall. An increase in esophageal pressure means that chest wall compliance is decreased as a result of intra-abdominal hypertension, pleural effusion, massive ascites, thoracic trauma, and edema of thoracic and abdominal tissues due to fluid resuscitation.

### 1. Assessing lung recruitability using a low flow pressure-volume curve

By using esophageal pressure measurement, a low flow pressure-volume (PV) curve can be partitioned into the chest wall PV curve and the lung PV curve. Knowing the effect of the chest wall on the respiratory system of patients may provide more information about lung recruitability. Differences in chest wall mechanics according to the stage of ARDS may influence the potential for alveolar recruitment. There may be high potential for recruitment if the chest wall PV curve is shifted to the right, and the lung PV curve shows a well-defined lower inflection point, a convex shape of the inspiratory limb, and large hysteresis<sup>7, 8</sup> (Figures 10-16).

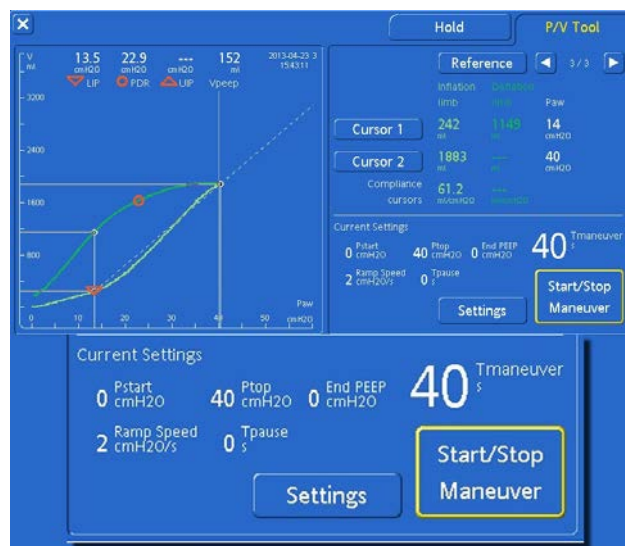

Figure 10: Settings for a pressure-volume curve using the PV Tool<sup>®</sup> Pro

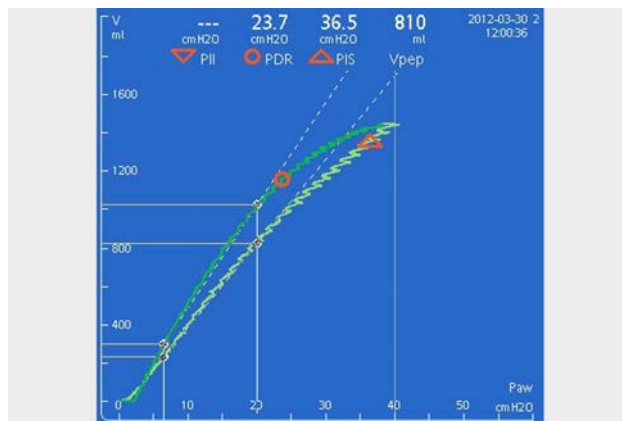


Figure 11: Respiratory system PV curve using airway pressure in a patient with low potential for recruitment

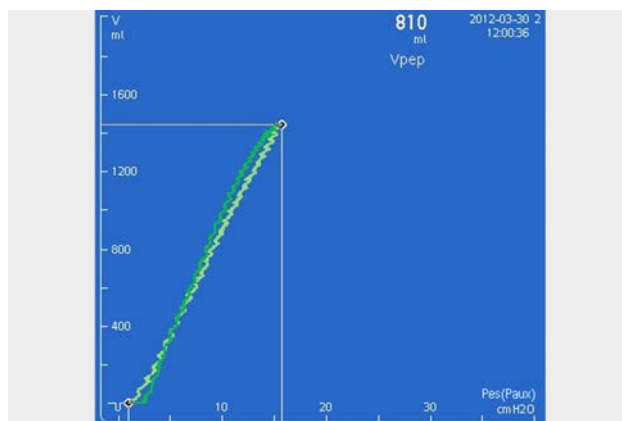


Figure 12: Chest wall PV curve using esophageal pressure in a patient with low potential for recruitment

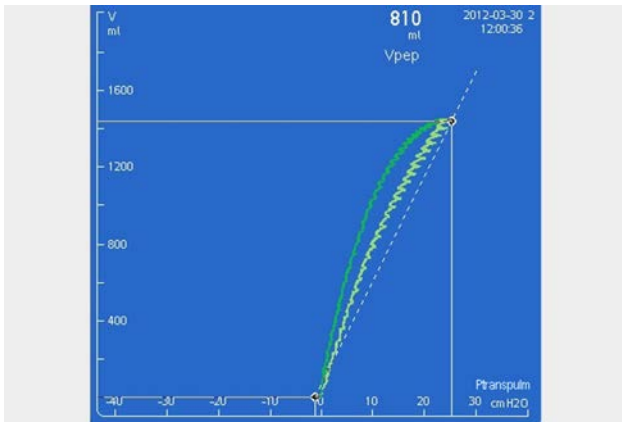


Figure 13: Lung P/V curve using transpulmonary pressure in an early onset ARDS patient. Note the absence of a low inflection point and a narrow hysteresis, meaning that the potential for lung recruitment is probably low. Note also that when airway pressure was increased to 40 cmH2O, transpulmonary pressure was around 25 cmH2O. This means that a recruitment maneuver would potentially harm the lung, while providing no benefit in terms of recruitment

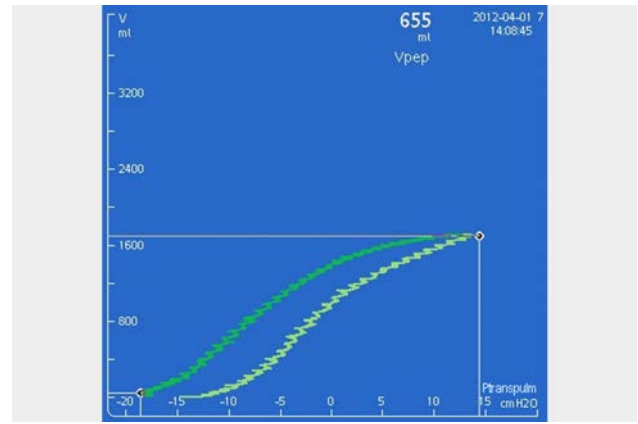


Figure 16: The shape of the inspiratory limb is convex. Lung P/V curve using transpulmonary pressure in an early onset ARDS patient. Note the presence of a well-defined lower inflection point and a large hysteresis, meaning that the potential for lung recruitment is probably high. Note also that when airway pressure was increased to 40 cmH2O, transpulmonary pressure was only around 15 cmH2O. This means that if a recruitment maneuver is performed, airway pressure should be set higher than 40 cmH2O

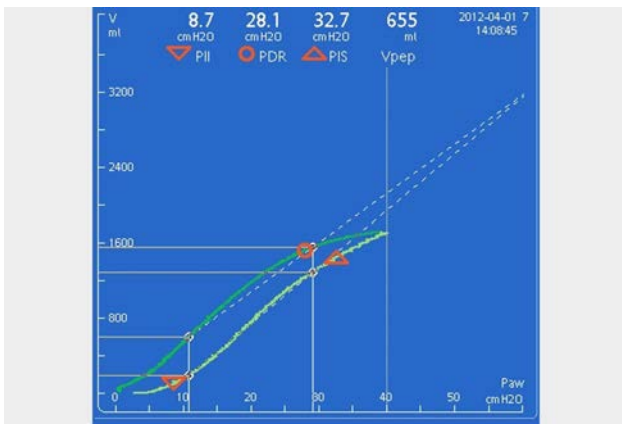


Figure 14: Respiratory system P/V curve using airway pressure in a patient with high potential for recruitment

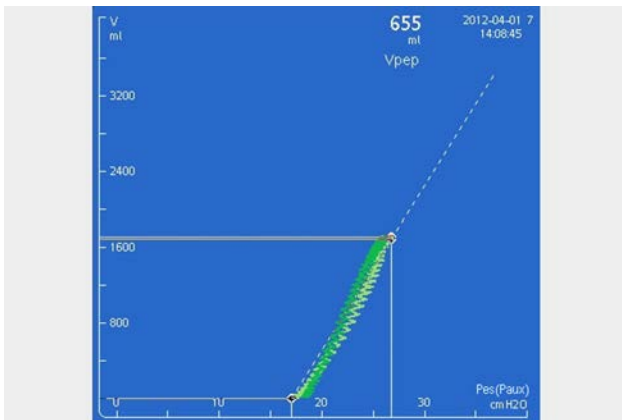


Figure 15: Chest wall P/V curve using esophageal pressure in a patient with high potential for recruitment

## 2. Titrating recruitment maneuver

By using esophageal pressure measurement, the pressure to recruit the lung can be titrated. The goal is to reach a transpulmonary pressure of around 20 cmH2O for the recruitment maneuver to fully recruit the lung and prevent excessive overdistension<sup>9</sup> (Figures 17-20). It is important to assess recruitability before performing a recruitment maneuver.

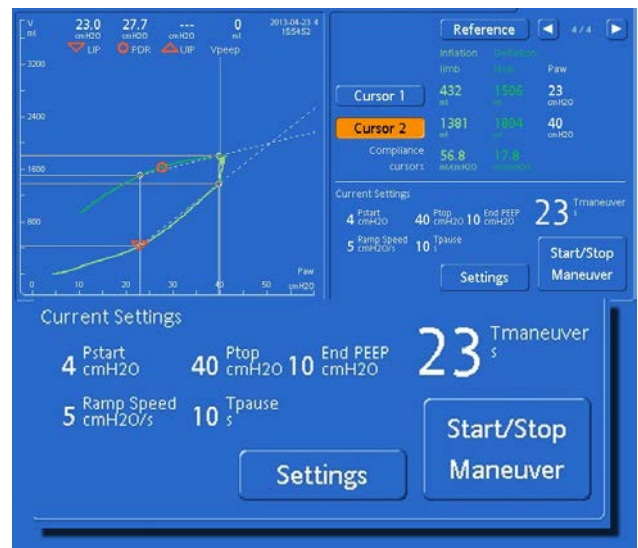

Figure 17: Settings for a recruitment maneuver with the PV Tool using a fast pressure increase (ramp speed at 5 cmH2O/s), a pause of 10 s at high pressure, and higher PEEP after the recruitment maneuver

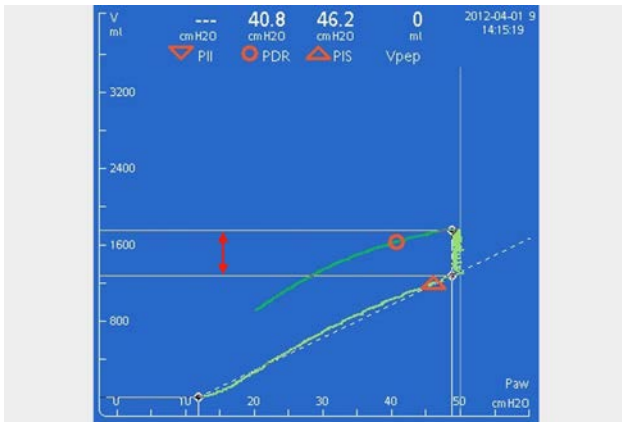


Figure 18: Airway pressure versus volume during a sustained inflation recruitment maneuver

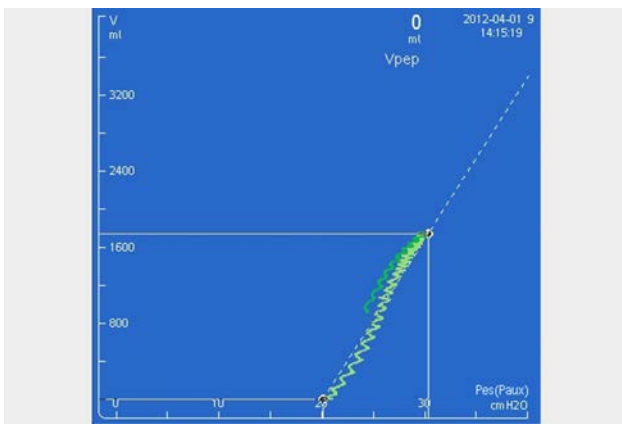


Figure 19: Esophageal pressure versus volume during a sustained inflation recruitment maneuver

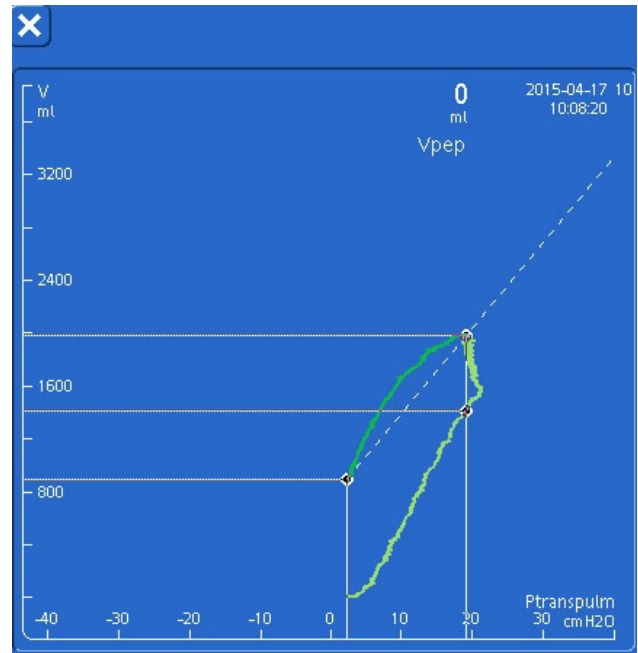


Figure 20: Sustained inflation recruitment maneuver performed with the PV Tool in an early onset ARDS patient (same patient as in Figures 12-14). Airway pressure (16), esophageal pressure (17) and transpulmonary pressure (18) versus volume during the recruitment maneuver. Note that the top airway pressure was set at 50 cmH<sub>2</sub>O in order to have transpulmonary pressure at around 20 cmH<sub>2</sub>O. The duration of the recruitment maneuver was 10 seconds. Note the increase in volume on the airway and transpulmonary pressure curves (red arrows), which is an assessment of the volume recruited during the recruitment maneuver

### 3. Setting PEEP

In ARDS patients, PEEP can be set in order to achieve a transpulmonary pressure of 2 to 5 cmH<sub>2</sub>O at end-expiration using an end-expiratory occlusion. The rationale is to prevent atelectrauma caused by repeated opening and closing of distal airways and alveoli. In a randomized controlled physiological study, setting PEEP according to transpulmonary pressure was associated with better oxygenation and respiratory system compliance than when using the standard ARDSnet PEEP-FiO<sub>2</sub> table<sup>10</sup> (Figure 21).

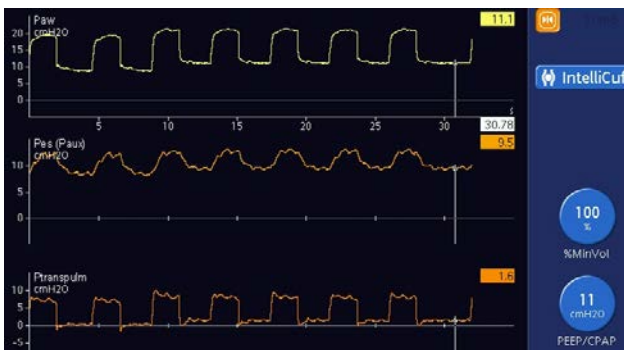
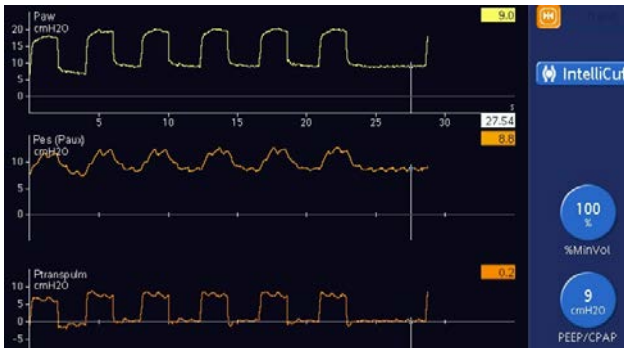
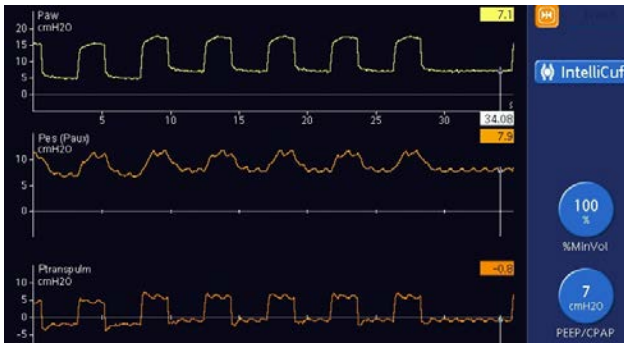


Figure 21: PEEP adjustment according to end-expiratory transpulmonary pressure in an early onset ARDS patient. In each figure, airway, esophageal, and transpulmonary pressures are displayed from top to bottom. The cursor is positioned at the end-expiratory occlusion. In the top figure, PEEP is 7 cmH<sub>2</sub>O. Transpulmonary pressure is negative at end-expiration with a high risk of atelectrauma. In the middle figure, PEEP is 9 cmH<sub>2</sub>O. Transpulmonary pressure is 0 at end-expiration. In the lower figure, PEEP is 11 cmH<sub>2</sub>O. Transpulmonary pressure is around 2 cmH<sub>2</sub>O at end-expiration, which should prevent atelectrauma

#### 4. Setting tidal volume and inspiratory pressures

Transpulmonary pressure at end-inspiration is measured during an end-inspiratory occlusion and assesses the stress applied to the lung. The recommendation is to set tidal volume or inspiratory pressure in order to keep transpulmonary pressure at end-inspiration below 15 cmH<sub>2</sub>O<sup>11</sup> (Figure 22).

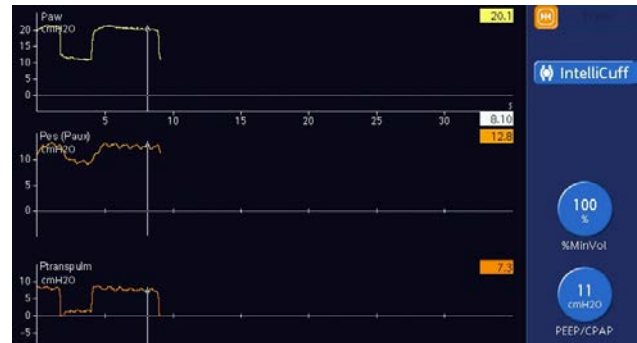


Figure 22: Tidal volume adjustment according to end-inspiratory transpulmonary pressure in an early onset ARDS patient (same patient as in Figure 19). From top to bottom, airway, esophageal, and transpulmonary pressures are displayed. The cursor is positioned at the end-inspiratory occlusion. Transpulmonary pressure is 7 cmH<sub>2</sub>O, which is safe in terms of global stress applied to the lung

### Other applications

In spontaneously breathing patients, respiratory muscle effort can be assessed by work of breathing or the esophageal pressure-time product. In addition, esophageal pressure measurement is very useful for assessing patient-ventilator synchrony, in particular auto-triggering, inspiratory trigger delay, and ineffective inspiratory efforts. Esophageal pressure measurement helps to maintain the minimum amount of effort required for safe, spontaneous breathing by measuring global lung stress and strain.

### Limitations

Inflating the balloon with an inappropriate volume or positioning the catheter incorrectly in the esophagus will lead to inaccurate measurements. In addition, there is a postural effect due mainly to the weight of mediastinum. It is recommended that esophageal pressure be measured in a semi-recumbent position. Finally, because there is a physiological regional variation in pleural pressure, esophageal pressure estimates the middle pleural pressure.



## References

1. Talmor D, Sarge T, O'Donnell C, Ritz R, Malhotra, Lisbon A, Loring S. Esophageal and transpulmonary pressures in acute respiratory failure. *Crit Care Med* 2006; 34:1389–1394
2. Gattinoni L, Chiumello D, Carlesso E, Valenza F. Benchto-bedside review: Chest wall elastance in acute lung injury/acute respiratory distress syndrome patients. *Critical Care* 2004, 8:350-355
3. Hess D, Bigatello L. The chest wall in acute lung injury/acute respiratory distress syndrome. *Curr Opin Crit Care* 2008;14:94–102
4. Akoumianaki E, Maggiore S, Valenza F, Bellani G, Jubran A, et al. The application of esophageal pressure measurement in patients with respiratory failure. *Am J Respir Crit Care Med* 2014;189:520-31
5. Baydur A, Cha EJ, Sassoon CS. Validation of esophageal balloon technique at different lung volumes and postures. *J Appl Physiol* 1987; 62:315–321
6. Yoshida T, Amato MBP, Grieco DL, Chen L, Lima CAS, Roldan R, et al. Esophageal manometry and regional transpulmonary pressure in lung injury. *Am J Respir Crit Care Med* 2018;197(8):1018-1026
7. Maggiore SM, Jonson B, Richard JC, Jaber S, Lemaire F, Brochard L. Alveolar derecruitment at decremental positive end-expiratory pressure levels in acute lung injury: Comparison with the lower inflection point, oxygenation, and compliance. *Am J Respir Crit Care Med* 2001;164:795–801
8. Demory D, Arnal JM, Wysocki M, Donati SY, Granier I, Corno G, Durand-Gasselín J. Recruitability of the lung estimated by the pressure volume curve hysteresis in ARDS patients. *Intensive Care Med* 2008; 34:2019–2025
9. Baedorf Kassis E, Loring SH, Talmor D. Recruitment maneuvers: using transpulmonary pressure to help Goldilocks. *Intensive Care Med.* 2017 Aug;43(8):1162-1163
10. Talmor D, Sarge T, Malhotra A, O'Donnell CR, Ritz R, Lisbon A, Novack V, Loring S. Mechanical ventilation guided by esophageal pressure in acute lung injury. *N Engl J Med* 2008;359:2095-2104
11. Chiumello D, Carlesso E, Cadringer P, Caironi P, Valenza F, Polli F, Tallarini F, Cozzi P, Cressoni M, Colombo A, Marini JJ, Gattinoni L. Lung stress and strain during mechanical ventilation of the Acute Respiratory Distress Syndrome. *Am J Respir Crit Care Med* 2008;178:346-55

---

Hamilton Medical AG

Via Crusch 8, 7402 Bonaduz, Switzerland

 +41 58 610 10 20

[info@hamilton-medical.com](mailto:info@hamilton-medical.com)

[www.hamilton-medical.com](http://www.hamilton-medical.com)